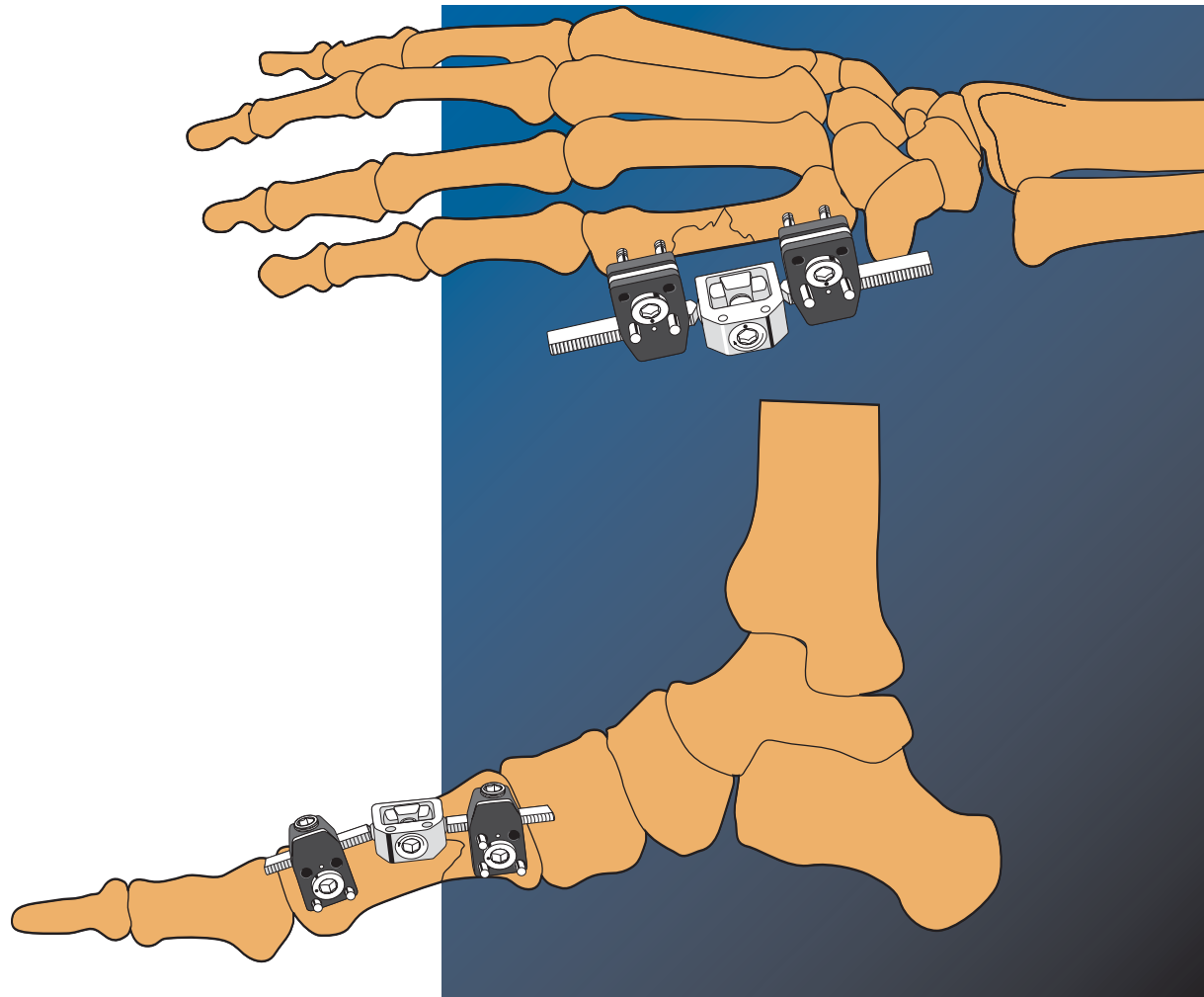

# Treatment of Fractures and Deformities in Small Bones

The Pennig Minifixator

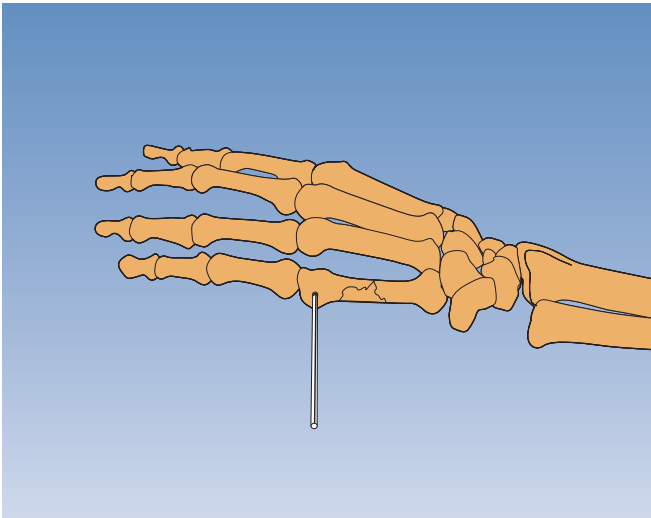
By Prof. Dr. D. Pennig

## METACARPAL FRACTURES

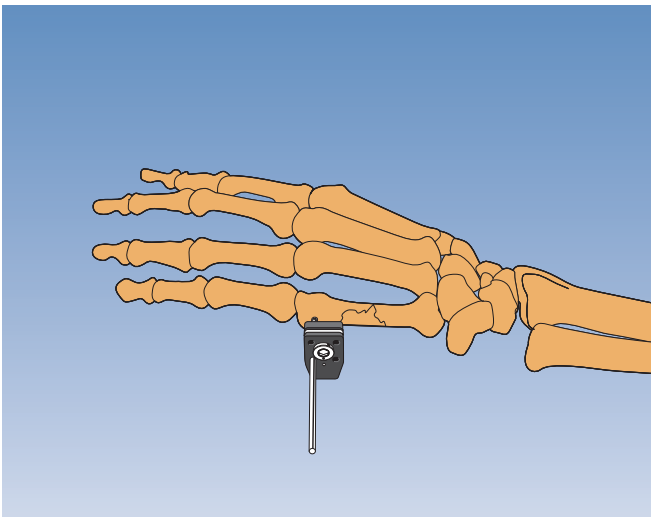
### Fifth metacarpal diaphyseal fractures

Insert threaded wire (2 mm; 100/15) closest to MCP joint first. Drill it into bone in the frontal plane, to penetrate far cortex by 1 mm. Use image intensification.

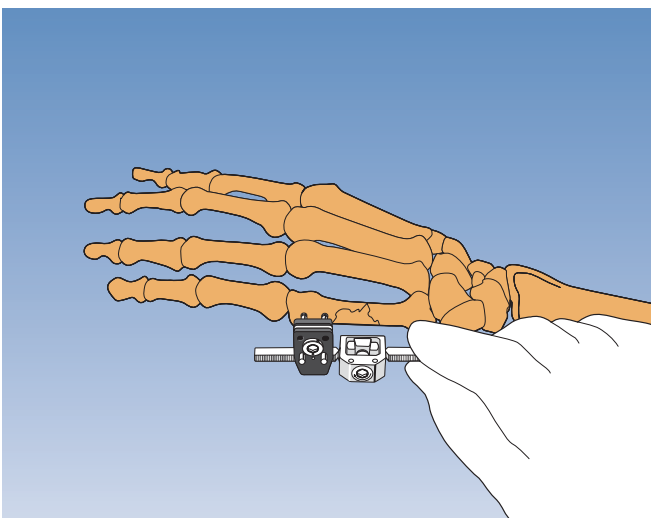
*Note: These wires can be backed out; they are not conical.*

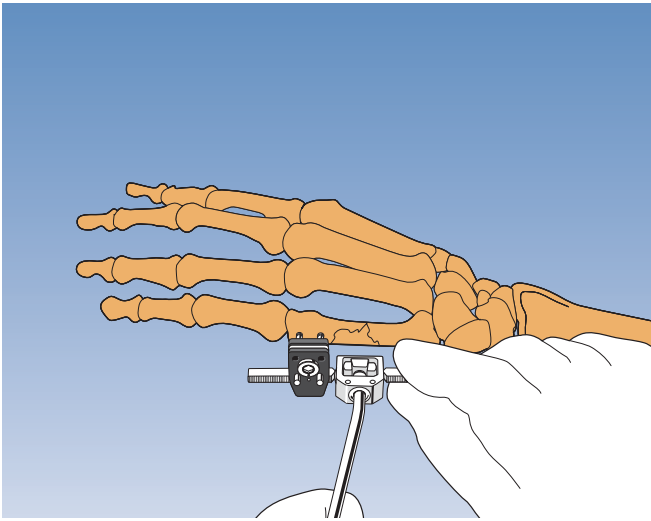


Place a standard clamp over the wire with dot on cam in line with dot on clamp. Head of cam must face away from bone. Position clamp 5-10 mm from skin and trim this wire (and all subsequent wires) so that 5 mm projects from clamp.

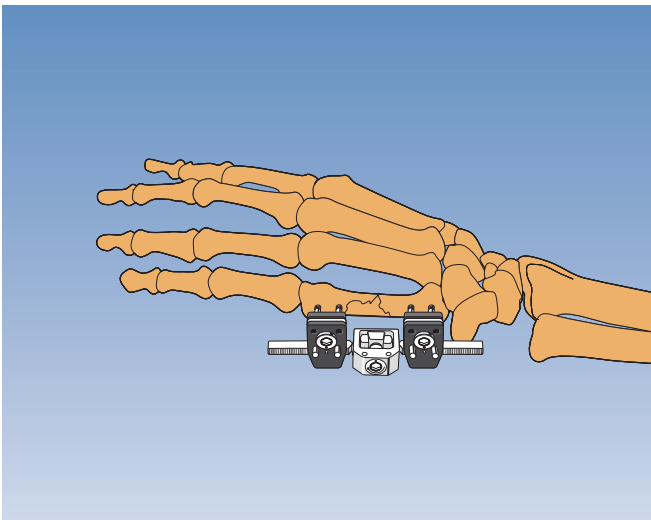


Insert second wire either axially (emerges from clamp parallel with first) or transversely (converges with first wire) depending on space available. Use image intensification. Choose appropriate length Minifixator body and attach one threaded bar to the clamp.

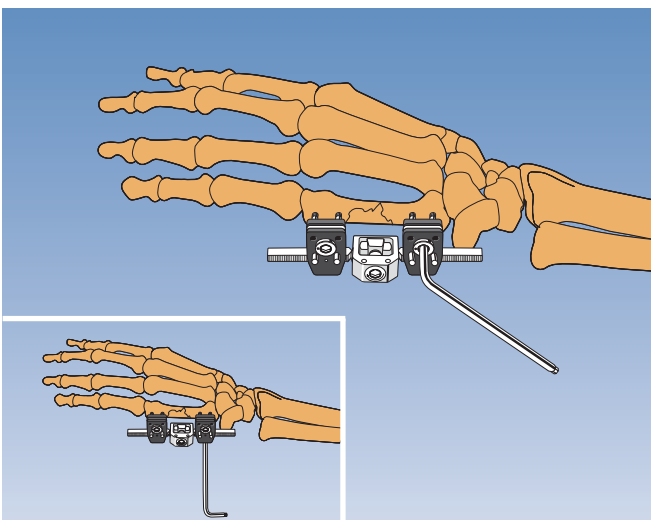




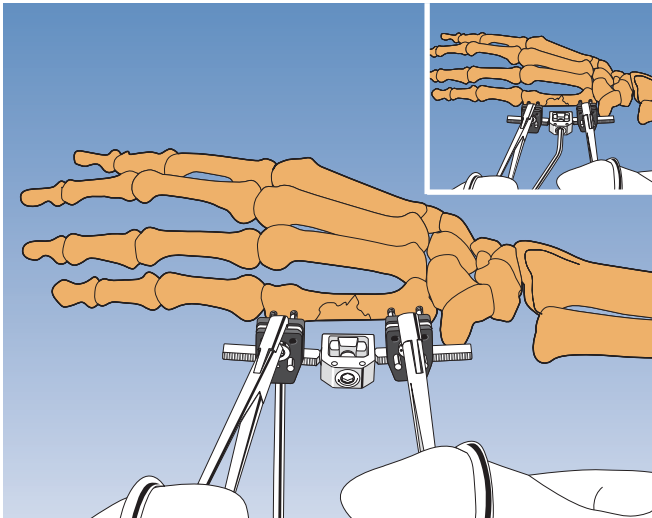
Tighten double ball-joint cam slightly and align fixator with long axis of bone.



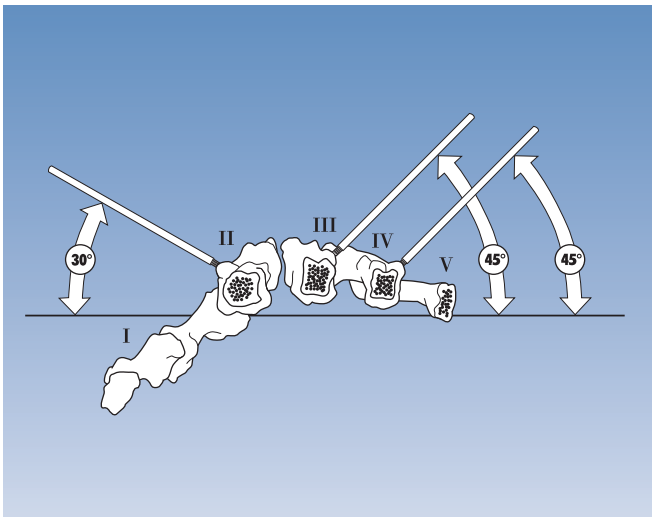
Attach second clamp and insert second set of wires, ensuring clamps have room to move on their bars to allow for final reduction.



Lock clamps to wires by turning cams. Lock one clamp to bar with its locking screw.



Reduce fracture using reduction forceps which distance surgeon's hands from radiation source. While maintaining reduction lock second clamp to bar and fully tighten double ball-joint. Trim wires to within 2 mm of clamps. Dressing should fully cover Minifixator. Encourage movements of fingers and adjacent joints.



**Special considerations in other metacarpal applications**

**1<sup>st</sup> Metacarpal**

Apply wires in the frontal plane.

**2<sup>nd</sup> Metacarpal**

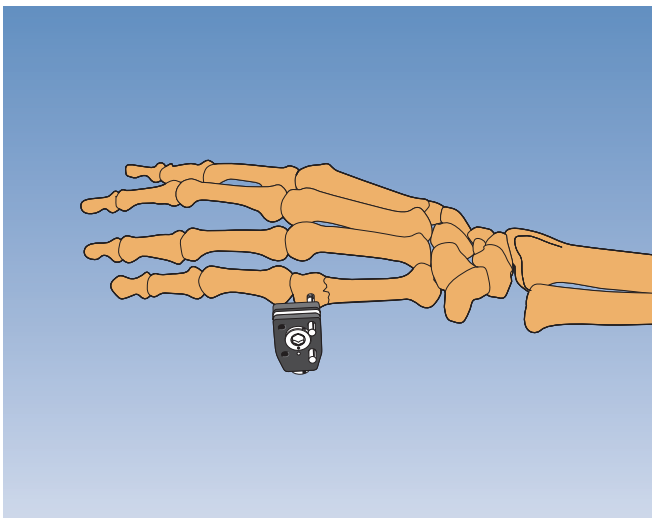
Incline wires dorsally at angle of 30° to the frontal plane.

**3<sup>rd</sup> and 4<sup>th</sup> Metacarpal**

Apply fixator from ulnar side.

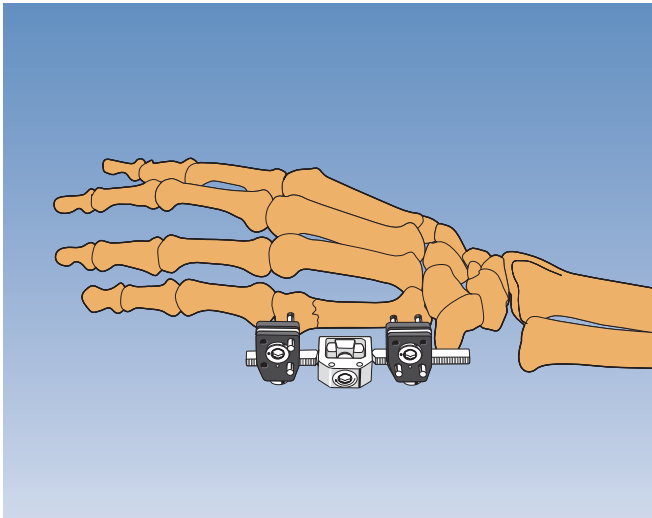
Incline wires dorsally at angle of 45° to the frontal plane.

*For outline technique, refer to "Fifth metacarpal diaphyseal fractures" above.*

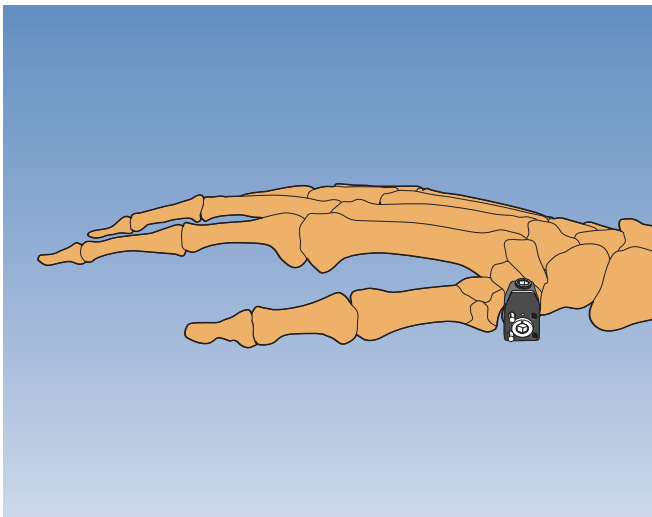


**Fifth metacarpal distal metaphyseal fractures**

2 mm threaded wires are drilled into the bone, using the clamp as its own template. Insert most volar wire in distal fragment first, in frontal plane, parallel to joint surface. Place clamp over the wire 5-10 mm from skin and insert second wire to converge with first.

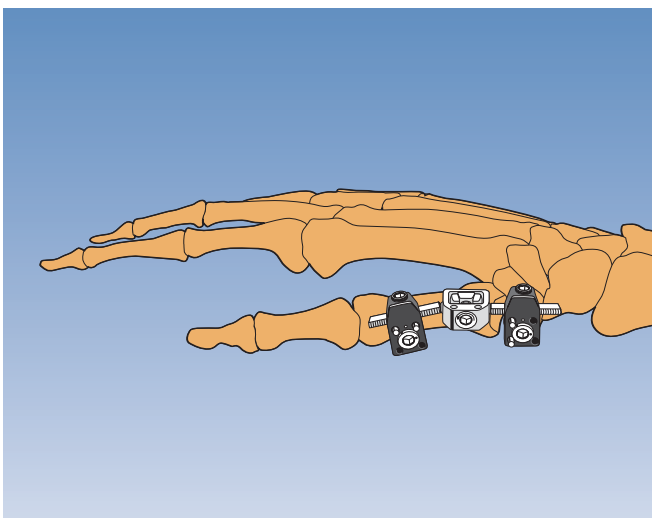


Attach Minifixator body (selected according to the dimensions of the bone) to clamp, align with long axis of bone and attach second clamp. Insert second set of wires in same manner, ENSURING CLAMPS HAVE ROOM TO MOVE ON THEIR BARS TO ALLOW FOR FINAL REDUCTION, which is achieved using manipulation forceps.

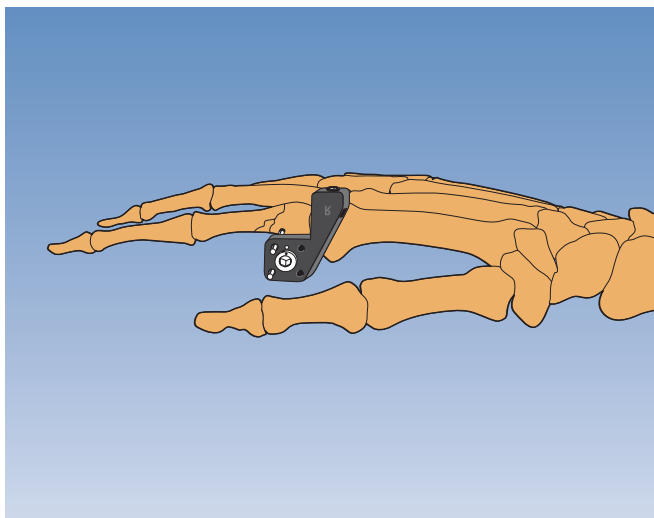


**Fractures at the base of the first metacarpal**  
2 mm threaded wires are drilled into the trapezium, and shaft of first metacarpal, using the clamp as its own template. Introduce first wire into trapezium, using semi-open approach to avoid injuring tendons. Slide clamp over first wire and insert second wire in a convergent mode.

*Note: Clamps are applied upside down and at least 5-10 mm from skin.*



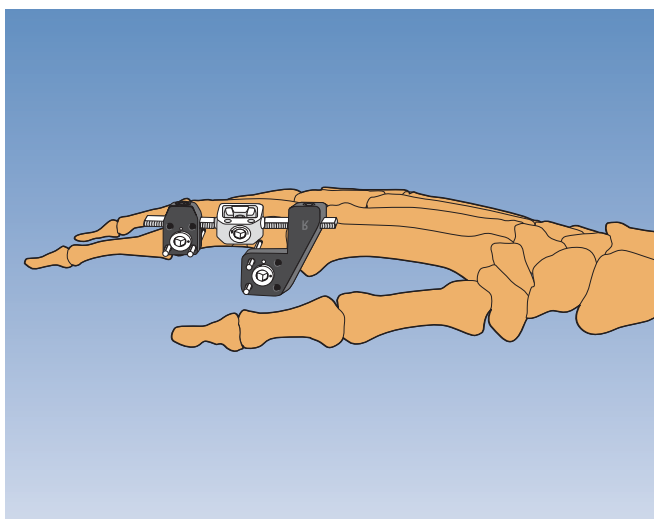
Attach Minifixator body (selected according to the dimensions of the bone) to first clamp and position second clamp. Insert second set of wires into metacarpal diaphysis in longitudinal plane, ENSURING CLAMPS HAVE ROOM TO MOVE ON THEIR BARS TO ALLOW FOR FINAL REDUCTION, which is achieved by ligamentotaxis using manipulation forceps.



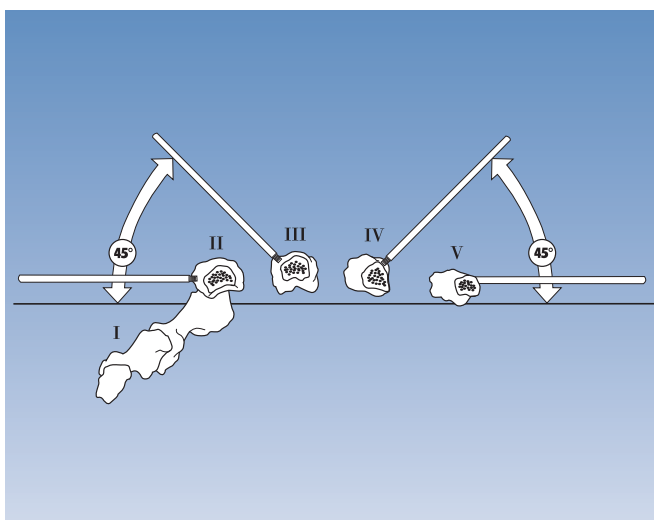
**PHALANGEAL FRACTURES**

**Fractures of the proximal phalanx of the index finger**

Use 2 mm threaded wires at the base of the proximal phalanx and 1.6 mm wires at more distal sites, using the clamp as its own template. Insert first wire in frontal plane, on radial aspect of base of phalanx. Place standard or L-clamp over wire, upside down, 5-10 mm from skin. Insert second wire dorsal to first (converges).



Attach Minifixator body (selected according to the dimensions of the bone) to clamp, align with long axis of bone and attach second clamp. Insert second set of wires, ENSURING CLAMPS HAVE ROOM TO MOVE ON THEIR BARS TO ALLOW FOR FINAL REDUCTION, which is achieved using manipulation forceps.



**Special considerations in phalangeal applications in other digits**

**1<sup>st</sup> Digit**

Apply fixator from radial side in frontal plane.

**3<sup>rd</sup> Digit**

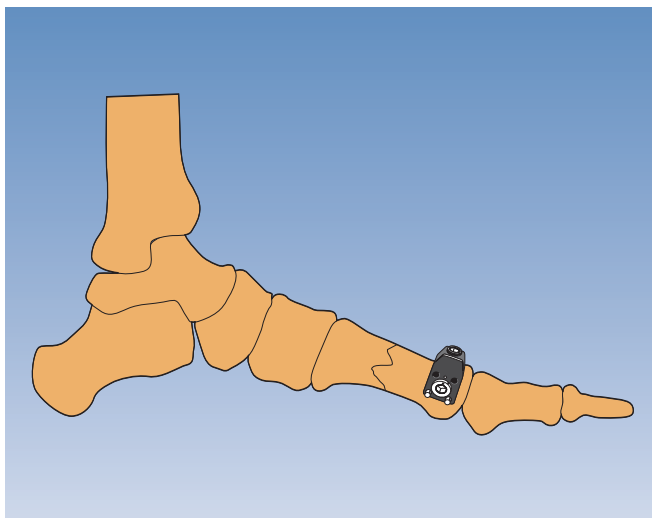
Incline wires dorsally at angle of 45° to the frontal plane.

**4<sup>th</sup> Digit**

Apply fixator from ulnar side. Incline wires dorsally at angle of 45° to the frontal plane.

**5<sup>th</sup> Digit**

Apply fixator from ulnar side in frontal plane.

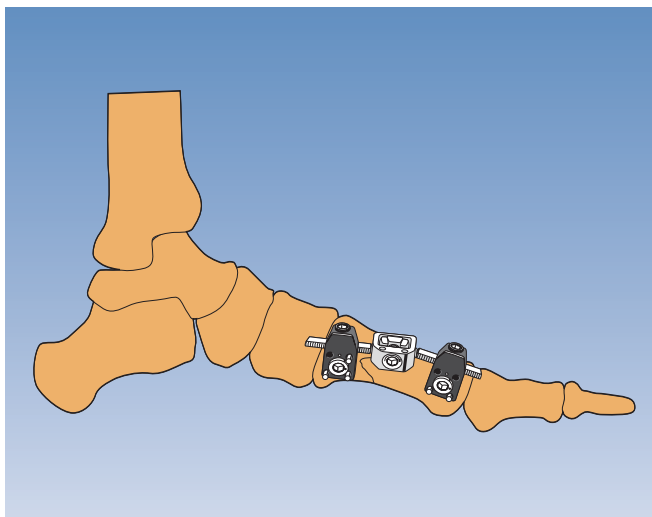


## METATARSAL FRACTURES

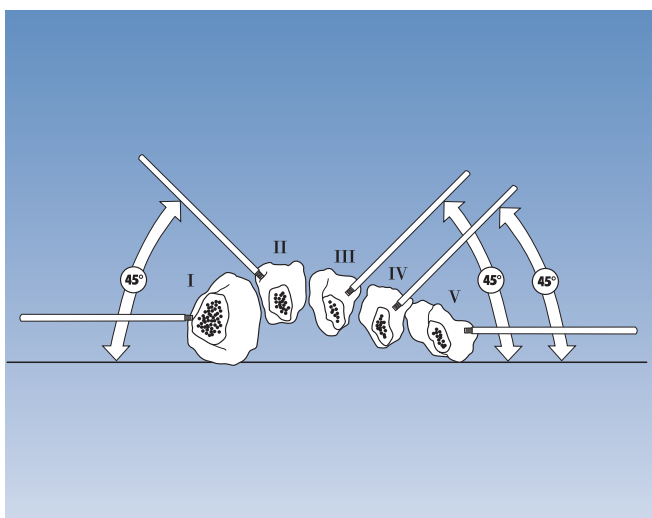
### First metatarsal diaphyseal fractures

2 mm threaded wires are drilled into the bone, using the clamp as its own template. Wire closest to the MTP joint is inserted first, in the frontal plane. Place clamp over wire, and insert second wire axially or transversely (depending on space available) under image intensification.

*Note: Clamps are applied upside down and at least 5-10 mm from skin.*



Attach Minifixator body (selected according to the dimensions of the bone) to clamp, align with long axis of bone and attach second clamp. Insert three wires in the second clamp, ENSURING CLAMPS HAVE ROOM TO MOVE ON THEIR BARS TO ALLOW FOR FINAL REDUCTION, which is achieved using manipulation forceps.



### Special considerations in other metatarsal applications

#### 2<sup>nd</sup> Metatarsal

Incline wires dorsally at angle of 45° to the frontal plane.

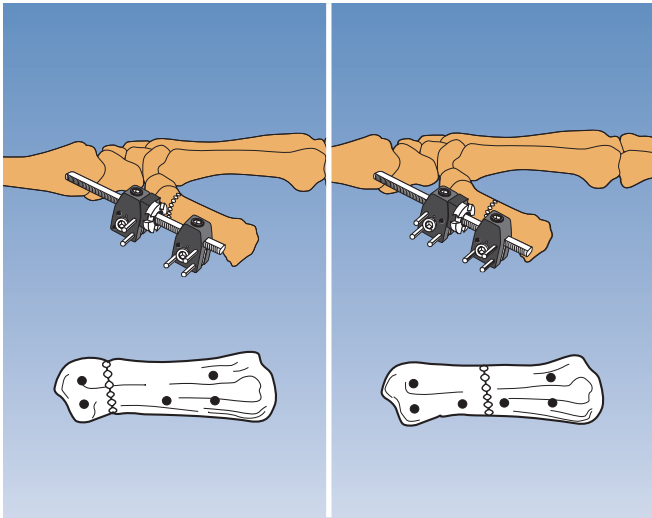
#### 3<sup>rd</sup> and 4<sup>th</sup> Metatarsal

Incline wires dorsally at angle of 45° to the frontal plane.

#### 5<sup>th</sup> Metatarsal

Apply fixator in the frontal plane.

*For outline technique, refer to "Fifth metacarpal diaphyseal fractures" above.*

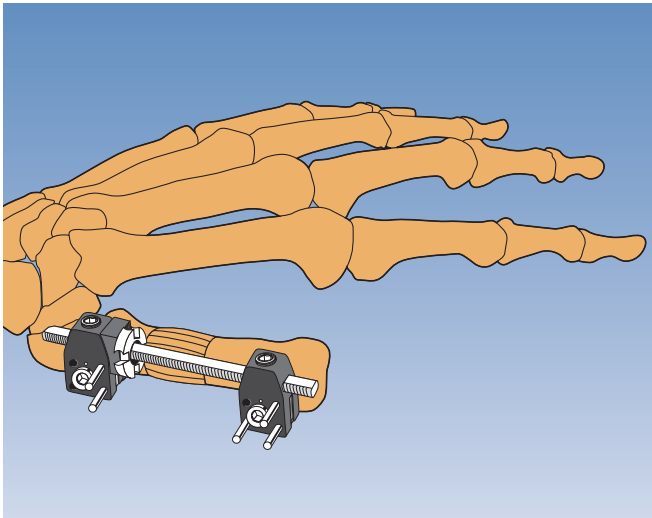


## LENGTHENING AND BONE TRANSPORT

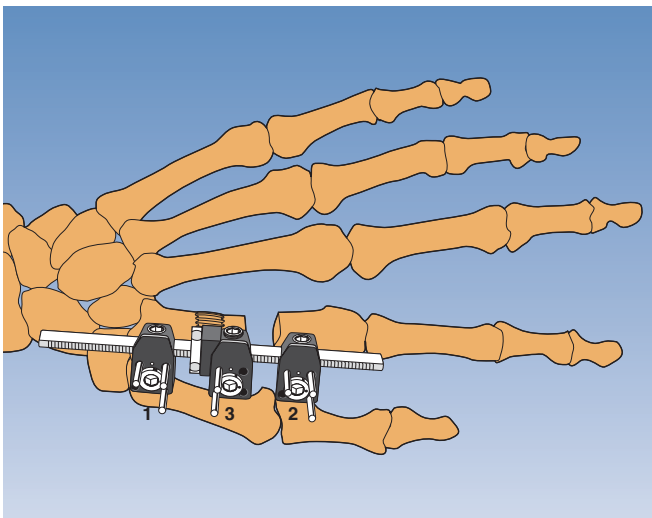
### Lengthening

Apply lengthening bar with standard clamps or L-clamps in the frontal plane using 2 mm wires. To increase stability in osteoporotic bone or in the metatarsals, add a 3rd wire in each clamp. Place the spacer and the compression-distraction nut on the bar before applying the second clamp. Perform the osteotomy.

*Note: Ensure spacer is between compression-distraction nut and standard clamp to avoid tilting the clamp.*



Start distraction at a rate of 0.5 mm per day (one quarter turn of the nut twice a day) after a waiting period of 7-10 days. Increase or reduce the distraction rate depending on the ossification.



### Bone Transport

Use a lengthening bar with three clamps. Apply two clamps to the larger segment and perform the osteotomy (preferably metaphyseal) between them. Align the segments prior to wire insertion. Apply the clamps in the order indicated in the picture. If shortening is present at the end of transport, loosen the clamp locking nut of clamp 2 and distract between clamp 1 and 3.


*Note: See spacer between compression-distraction nut and moving clamp.*



The Orthofix Quality System has been certified to be in compliance with the requirements of:

- Medical Devices Directive 93/42/EEC, Annex II - (Full Quality System)
- International Standards ISO 13485 / ISO 9001 for external fixator devices, implants for osteosynthesis and related instruments.



 See "Orthofix External Fixation System" instruction leaflet (PQ EXF) prior to use.

Manufactured by: ORTHOFIX Srl.  
Via Delle Nazioni 9  
37012 Bussolengo (Verona)  
Italy

Telephone 0039-0456719000  
Fax 0039-0456719380



Your Distributor is:

EF-0406-QR-E0 B

Adult & Pediatric Deformity Correction | Fixation | Bone Growth Stimulation | Foot & Ankle