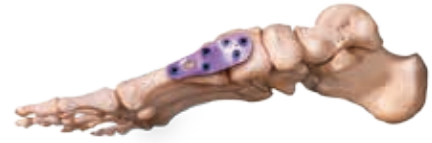



Treatment of Hallux Valgus with the Orthofix Contours LPS (Lapidus Plating System)

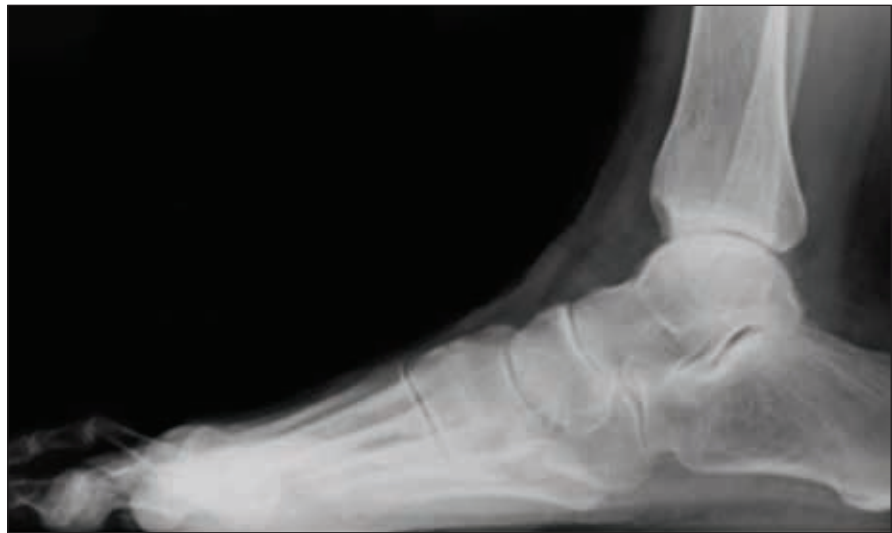
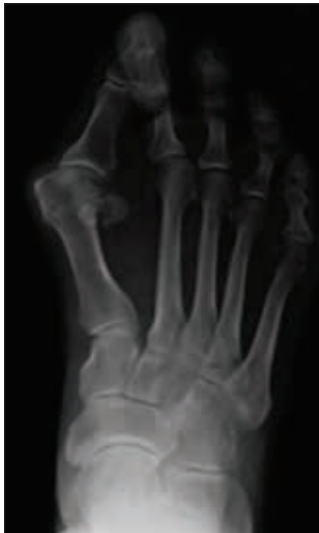
Case History

A 73-year-old female presented with chronic pain in her right foot. She had developed pain along the bottom of her foot and cross-over of the 2nd toe. The patient had been using accommodative shoes, modification and orthosis, with minimal relief.

Physical Examination

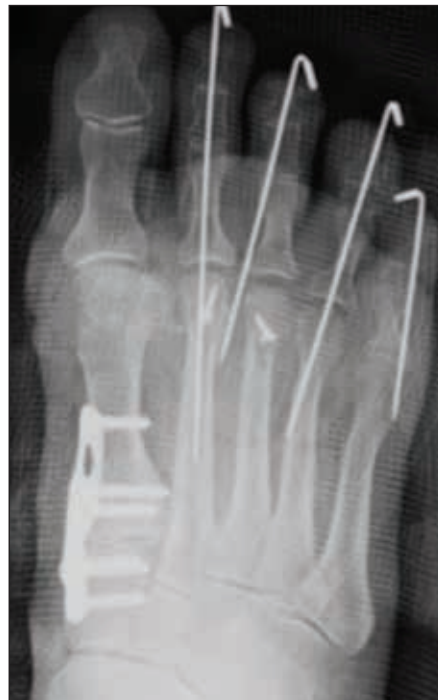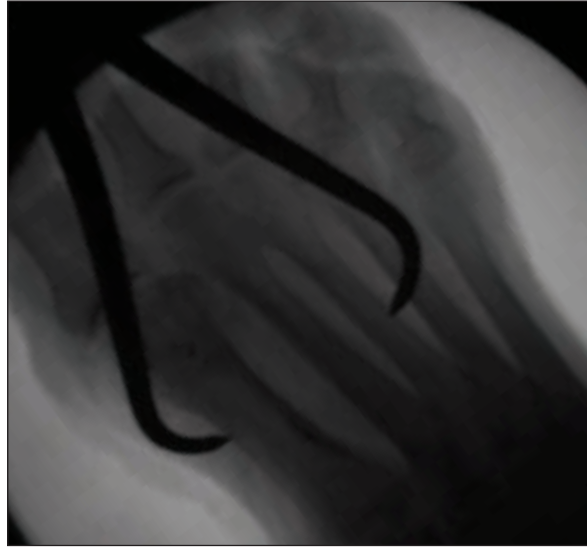
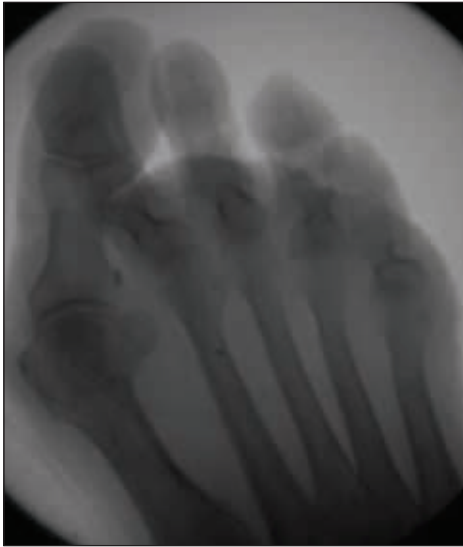- Slightly antalgic gait
- Hyper-mobile 1st tarsometatarsal (TMT) joint
- Cross-over of 2nd toe
- Intractable plantar keratosis (IPK)
- Dislocated lesser metatarsal-phalangeal (MTP) joints
- Normal arch
- Good ankle and subtalar motion
- Palpable DP/PT
- Decreased sensation of DMHC Nerve



Case Study | Contours LPS

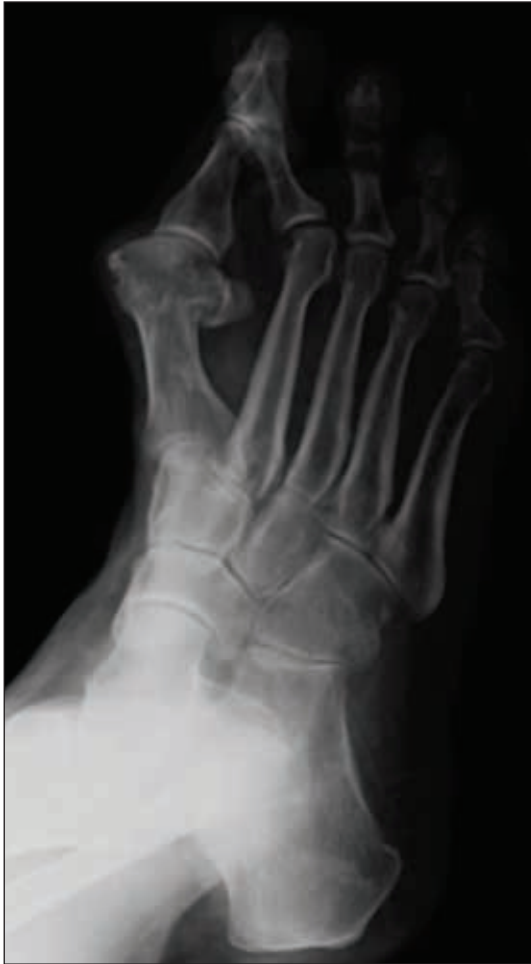Surgical Procedure

A dorsal-medial incision was made over the 1st metatarsal; from the 1st metatarsal-phalangeal joint (MTPJ) to the 1st tarsal-metatarsal (TMT). The 1st TMT joint was prepared, the distal soft tissue was balanced, and the intermetatarsal (IM) angle was reduced. Appropriate medial column plantar flexion was obtained. The Contours Lapidus plate was applied using provisional (K-wire) fixation. One (1) proximal screw was inserted and axial compression of the TMT joint performed. Alignment was checked radiographically and clinically. The remaining screws were drilled and placed. Screw lengths were confirmed via multi-planar fluoroscopy. The intercuneiform joint was not violated. After restoration of the normal medial column anatomy, the lesser toe deformities were addressed.

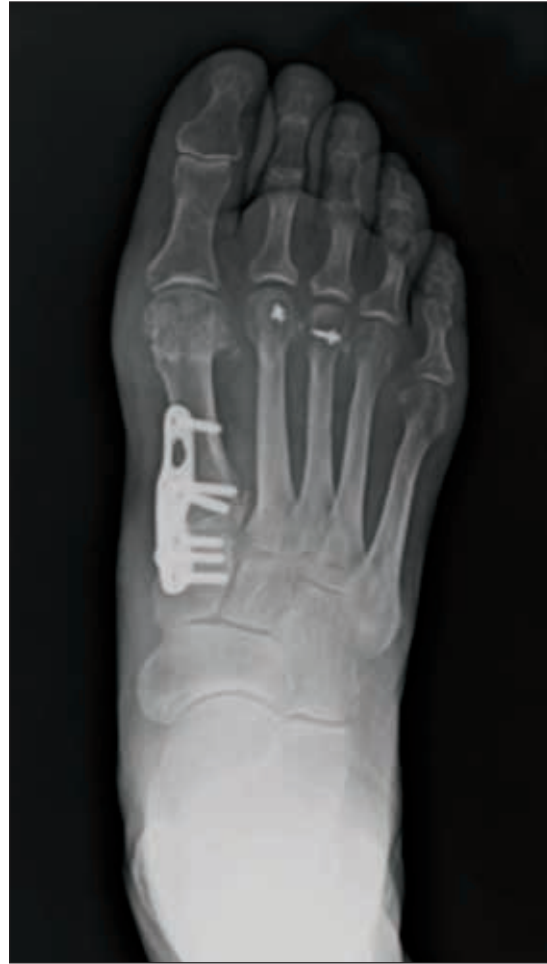

Post-Operative Results and Course of Treatment

Sutures were removed at 3 weeks and toe strapping performed. Lesser toe pins were removed at 4-6 weeks postop and progressive weight bearing allowed. Massage, as well as active and passive range of motion (ROM) therapy initiated once full weight-bearing was achieved. At three months, the patient is delighted and back to full activity. Afternoon / evening swelling is expected up to the year mark and is addressed with compressive dressings and massage. She is eager to correct her contralateral foot deformity.



Pre-op



Post-op

Surgeon Information

John S. Reach, Jr., M.Sc., M.D., is Director of Yale's Foot and Ankle Section and Assistant Professor in the Department of Orthopaedic Surgery, Yale University School of Medicine. Dr. Reach is a per diem consultant to Orthofix, Inc., serving in an advisory role.

INDICATIONS FOR USE:

The Contours Lapidus Plating System is intended for revision procedures and joint fusion in the small bones of the foot.

Caution: Federal law (USA) restricts this device to sale by or on the order of a physician.

Proper surgical procedure is the responsibility of the medical professional. Operative techniques are furnished as an informative guideline. Each surgeon must evaluate the appropriateness of a technique based on his or her personal medical credentials and experience. Please refer to the "Instructions for Use" supplied with the product for full information on indications for use, contraindications, warnings, precautions, adverse reactions information and sterilization.



Manufactured by:
ORTHOFIX Srl
Via Delle Nazioni 9, 37012 Bussolengo (Verona), Italy
Telephone +39 045 6719000, Fax +39 045 6719380

Distributed by:



Instructions for Use: See actual package insert for Instructions for Use.

Caution: Federal law (USA) restricts this device to sale by or on the order of a physician. Proper surgical procedure is the responsibility of the medical professional. Operative techniques are furnished as an informative guideline. Each surgeon must evaluate the appropriateness of a technique based on his or her personal medical credentials and experience. Please refer to the "Instructions for Use" supplied with the product for specific information on indications for use, contraindications, warnings, precautions, adverse reactions and sterilization.