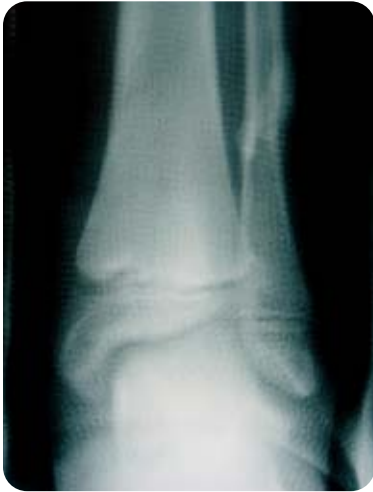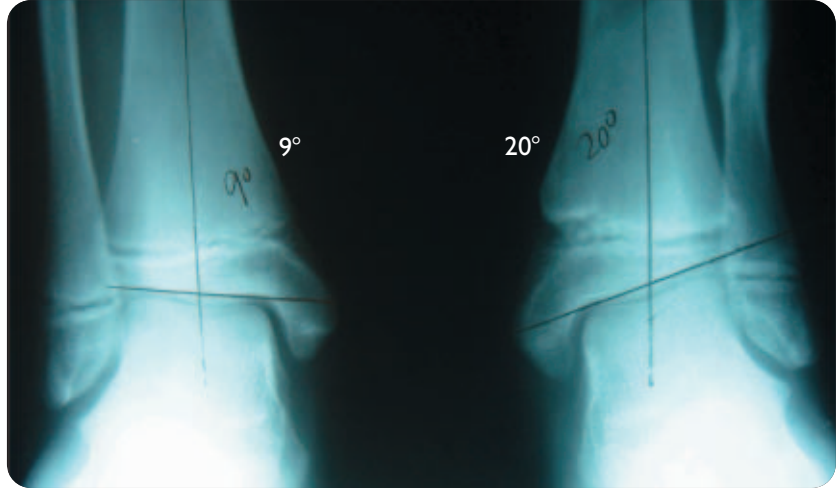


Ankle Valgus Left Ankle Fracture

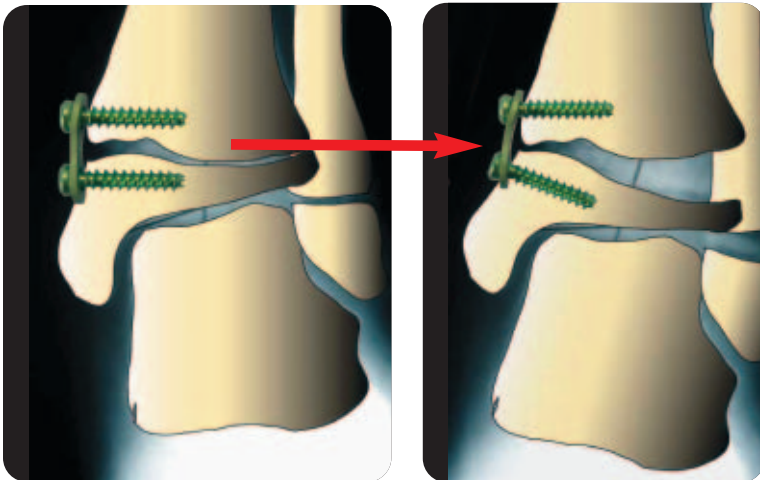
Case study provided by Peter M. Stevens, M.D., University of Utah



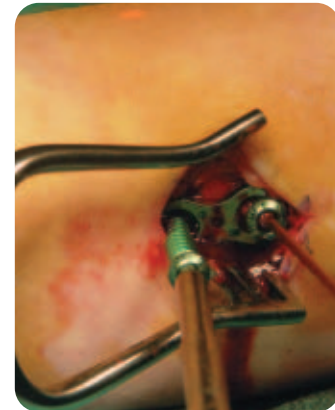12 Yr. Old Boy
Closed Reduction
Cast x 6 Weeks

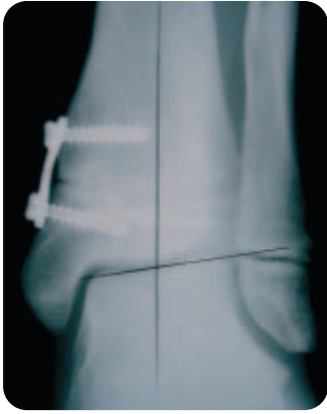

Healed Fracture
20° Ankle Valgus

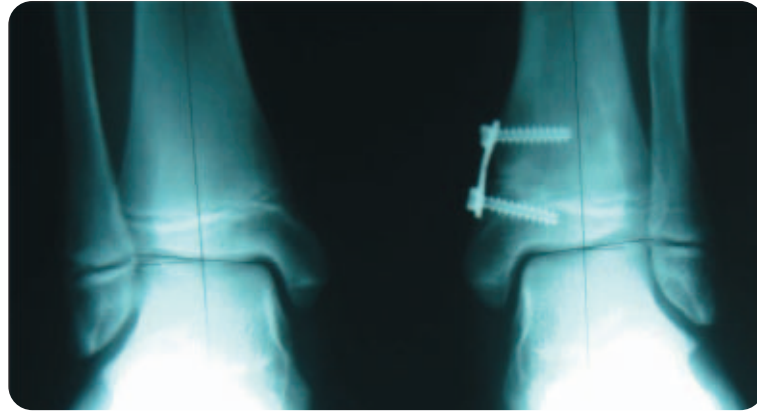


Diverging screws function
like a hinge to avoid
physis compression.

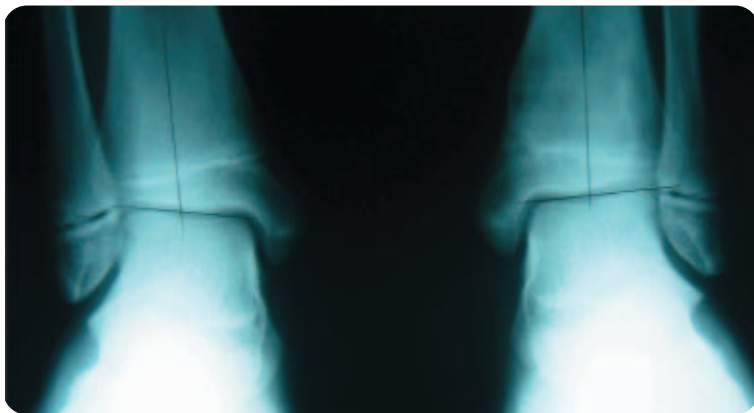




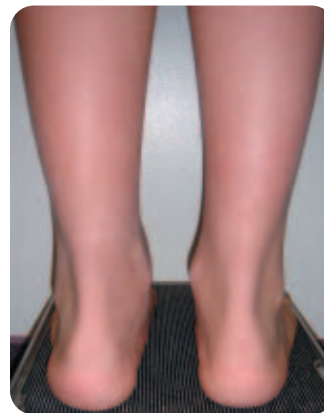4 Months /p
Guided Growth



7 Months /p
Guided Growth



6 Months /p
eight-Plate Removal



Hemi-Epiphysiodesis and Guided Growth References

- Hemi-Epiphysiodesis for Deformity Management
P. Stevens, Abstract, IPOS, Orlando, FL, USA, 12/03/2005
- Hypophosphatemic Rickets: The Role of Hemi-epiphysiodesis
E. Novais, MD and P. Stevens, MD, J. Pediatr. Orthop.,
Vol. 26, No. 2, March/April 2006
- Hemiepiphysiodesis for Posttraumatic Tibial Valgus
P. Stevens, Felicity Pease, J. Pediatr. Orthop.,
Vol. 26, No. 3, May/June 2006
- Guided Growth for Angular Correction
Peter Stevens, Abstract, POSNA, San Diego, CA, USA,
May 3-6, 2006

Indications

The eight-Plate is indicated for any angular deformity in a growing child/adolescent who would otherwise require an osteotomy.

Contraindications

The eight-Plate should not be used for adult deformities or where the growth plate has closed, such as due to trauma, infection or skeletal maturity.

eight-plate.com



 **ORTHOFIX**[®]
ALWAYS INNOVATING

For more information contact your local representative or call 1.800.BoneFix
www.orthofix.com